

## CHAPTER 5

# Sampling: Blood-Taking and Cultures

Helen Parry and Lynn Lambert

University Hospital Birmingham, Birmingham, UK

### OVERVIEW

By the end of this chapter you should be able to:

- understand the indications and contraindications for phlebotomy
- identify and understand the relevant anatomy
- be aware of different types of blood sampling devices
- describe the procedure of blood sampling
- appreciate when to take samples for blood culture
- use a blood culture sampling technique that minimises the risk of contamination.

## Phlebotomy

### Indications

- Profile testing, e.g. urea, electrolytes, liver function testing.
- Investigation of specific diseases, e.g. cortisol in Cushing's syndrome.
- Monitoring of hormones, therapeutic drugs and tumour markers.
- Toxicology, e.g. paracetamol levels.
- Venesection for therapeutic management of polycythaemia rubra vera.
- Sampling according to research protocols (ensure that you have consent).

### Contraindications

- Infection at the site of access, e.g. cellulitis.
- Bleeding tendencies (relative contraindication), e.g. on warfarin
- Thrombophlebitis.
- Taking sample from 'drip arm' (stop infusion and wait for at least 2 minutes before sampling).

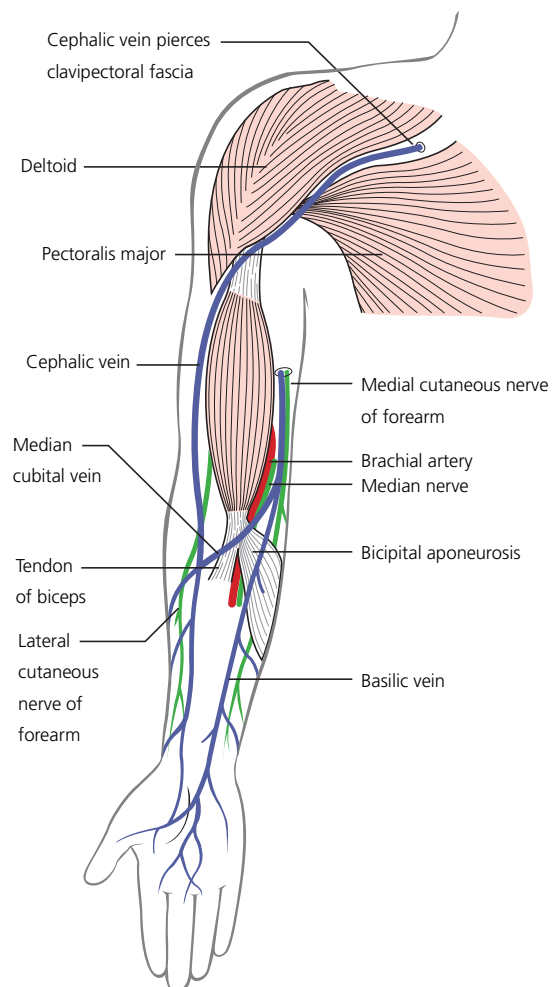
### Points of access

- Antecubital fossa (this is the most commonly used site and contains the basilic, cephalic and median cubital veins).
- Forearm, hand and digital veins (these can often be accessed using a butterfly needle).
- Femoral vein.

## Landmarks and anatomy

### Antecubital fossa

The antecubital fossa contains important vasculature for venepuncture. With the arm in the anatomical position and flexed, the biceps tendon is easily palpated and is located slightly medially within the fossa. Medially is the basilic vein and this divides to produce the median cubital vein (see Figure 5.1). The median cubital



**Figure 5.1** Venous drainage of the upper limb. (From Faiz O, Moffat D. (2006) *Anatomy at a Glance*, 2nd edn. Blackwell Publishing, Oxford, with permission.)

**Table 5.1** A summary of blood collection bottles (adapted from www.vacutette.com).

Bottle lid colour	Tube contents	Tests
Purple	EDTA (ethylenediamine-tetraacetic acid)	Full blood count, ESR, malaria screen, tacrolimus, cyclosporin, HbA1c, PCR analysis, cross-match and group and save
Gold	Clotting accelerator and separation gel	Biochemistry testing, tumour markers, endocrine testing
Light blue	Trisodium citrate	Coagulation testing
Red	Clotting accelerator	Serology, vancomycin, immunology, insulin, B12, folate
Grey	Sodium fluoride/potassium oxalate	Glucose
Green	Lithium heparin	Ammonia
Royal blue	Sodium heparin	Trace elements

vein combines with the cephalic vein (located medially in the antecubital fossa.) and is often used for venepuncture.

## Collection

There are different types of collection bottle depending on the test being performed. As a rule of thumb, anything for haematological investigation, group and save or DNA analysis such as PCR amplification requires blood collection in an EDTA (ethylenediaminetetraacetic acid) collection tube. This tube usually has a purple lid. Biochemical investigations are collected in tubes containing a clotting accelerator and separation gel. These are usually gold or yellow. Clotting investigations require trisodium citrate tubes which are usually light blue in colour. Table 5.1 is a guide for blood bottles in the UK. Check local guidelines for further information.

Samples should be delivered to the laboratory as soon as taken and always the same day.

## Equipment: methods for blood collection

There are several means by which a phlebotomist may obtain blood. The pros and cons of each can be found in Box 5.1.

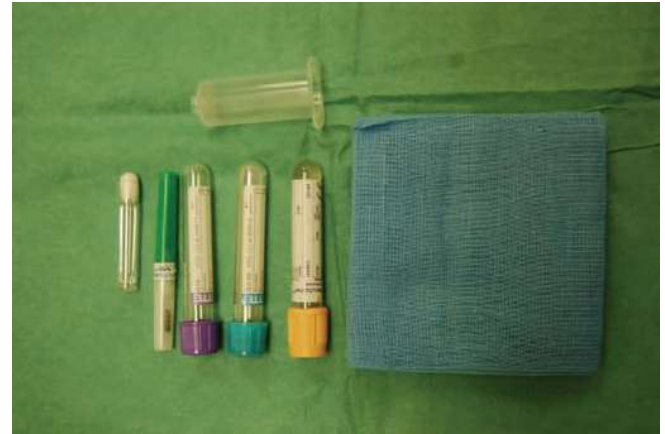### Box 5.1 Pros and cons of the different equipment used in phlebotomy

#### Pros

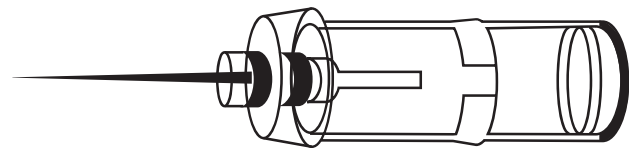
- A Vacutainer™ system is safest.
- A needle and syringe or use of a butterfly demonstrates a flashback to confirm the needle has entered the vein.

#### Cons

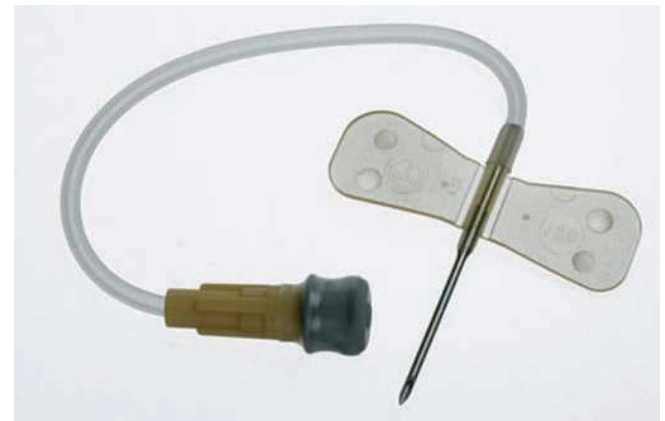
- A multipurpose needle with a tube holder does not allow for a flashback. Therefore, until a Vacutainer™ tube is loaded onto the tube holder it is unclear if the vein has been successfully punctured.
- When using a Vacutainer™ system, the loading of different blood collection tubes whilst keeping the needle still within the vein requires some dexterity and practice.



**Figure 5.2** Equipment for phlebotomy.



**Figure 5.3** A multisampling needle and collecting tube.



**Figure 5.4** A butterfly needle.

## Vacutainer™ system

One of the safest means of phlebotomy involves the use of a Vacutainer™ system. This consists of a cylindrical clear plastic collecting device, known as a tube holder, which is attached to either a multisampling needle (Figure 5.3) or a butterfly needle and luer adaptor (Figure 5.4). Vacutainer™ blood bottles are loaded onto the luer adaptor within the tube holder; the vacuum present causes blood to flow directly from the vein and into the bottle (Figure 5.5).

## Needle and syringe

This is the traditional method for phlebotomy. It is simply a needle (normally 21G – green) attached to a syringe.

## Step-by-step guide: venepuncture

**Give a full explanation to the patient in simple terms and ensure they consent to the procedure. Prepare equipment (Figure 5.2)**

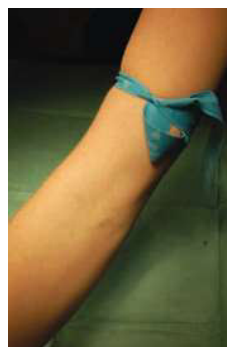

**Figure 5.5** Loading of the vacutainer bottle into the tube holder.

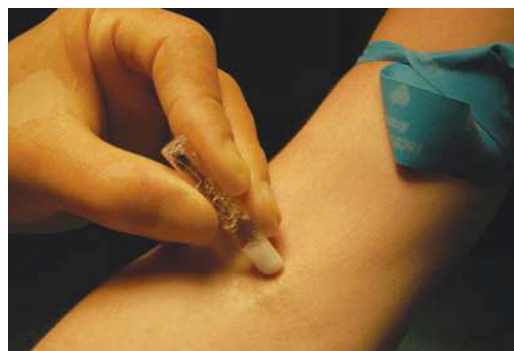- 1 Wear gloves and apron at all times.
- 2 Inquire whether the patient is left- or right-handed and attempt venepuncture initially in the non-dominant arm.
- 3 Place the tourniquet above the site of venepuncture (usually this is above the antecubital fossa) (Figure 5.6a).
- 4 Leave for at least 20 seconds for the veins to fill; often it is helpful at this stage if the patient makes repetitive fist actions with their hand.
- 5 Feel and look for access sites. Often a 'bouncy' vein that is easily palpable is far easier and generally more successful for phlebotomy rather than a visible 'thready' vein. Usually the antecubital fossa is a good starting point. If no obvious vein is found, work down the arm feeling and looking for a more suitable vein, or alternatively try the other arm.
- 6 Once a site of access has been decided upon, wipe the skin carefully with an antiseptic wipe (2% chlorhexidine in 70% alcohol), working in circles from the centre outwards (Figure 5.6b).
- 7 With the needle attached to either a Vacutainer™ system or syringe, insert the bevel upwards, passing through the skin and into the vein (Figure 5.6c).
- 8 Attach collecting bottles or withdraw the plunger of the syringe. Collect blood.
- 9 Once enough blood has been collected, loosen the tourniquet.
- 10 Withdraw the needle and place a cotton ball over the access site. Secure with tape.
- 11 Dispose of the needle appropriately in a sharps box. Never leave sharps lying around.
- 12 If blood has been collected in a syringe, this will now need to be transferred to bottles.
- 13 Label bottles with patient details. Group and save samples or cross-matching samples must always be handwritten at the patient bedside, correlating information transcribed on the bottle with the patient themselves, their hospital wrist band and the collecting form.

## Complications and how to avoid them

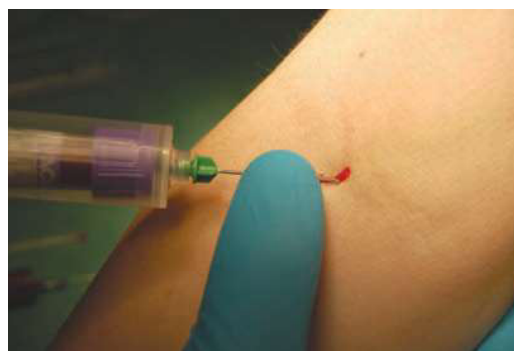- Infection at the puncture site. This can be minimised by cleaning the skin with an antiseptic wipe (e.g. 2% chlorhexidine/70% alcohol solution).
- Haematoma. This occurs more frequently if patients are on warfarin or steroid therapy. To avoid a haematoma, apply gentle pressure for 1–2 minutes after the procedure and release the tourniquet before removing the needle. Advise the patient to keep their arm straight.



(a)



(b)



(c)

**Figure 5.6** Step-by-step guide: venepuncture. (a) Apply a tourniquet to the upper arm. (b) Sterilise the skin using 2% chlorhexidine in 70% alcohol solution. (c) Attaching a collecting bottle to the Vacutainer™ system.

- Pain. This may be from the tourniquet or from venepuncture. A local anaesthetic cream may be applied to the skin to reduce the pain incurred.

## Blood cultures

### Indications

- To culture bacteria in cases of infection. The chances of successful culture are greatly improved if taken at the time of pyrexia.
- In the case of suspected endocarditis it is important to obtain blood from three different sites and at different times.
- If severe sepsis is present, at least one set should be drawn percutaneously and one from each indwelling vascular access device.

## Step-by-step guide: blood culture

Give a full explanation to the patient in simple terms and ensure they consent to the procedure. Prepare equipment (Figure 5.7)

- 1 Collect culture bottles, phlebotomy equipment and antiseptic stick (Figure 5.7).
- 2 Identify an accessible vein.
- 3 Ensure the skin over the vein is sterile by using an antiseptic (2% chlorhexidine in 70% alcohol solution). Allow to dry and do

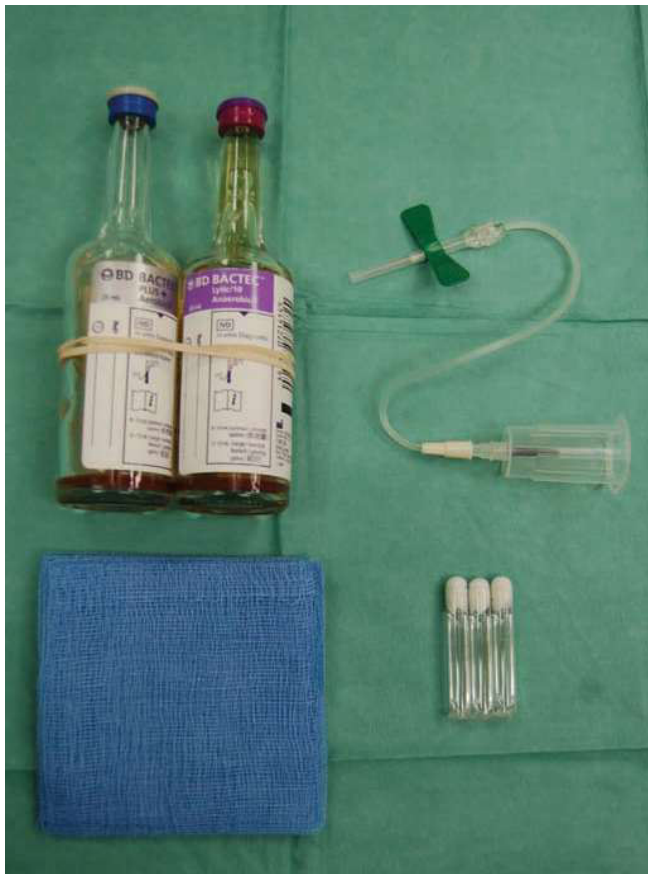

Figure 5.7 Equipment for taking cultures.

- 4 Clean the tops of an anaerobic and aerobic blood culture bottle using a chlorhexidine/alcohol wipe. Allow to dry fully (Figure 5.8a,b).
- 5 Collect at least 20 mL blood in a syringe, using a 21G (green) needle or vacutainer system (Figure 5.8c,d).
- 6 If using a needle and syringe, be sure to use a clean needle for each culture bottle and place at least 10 mL blood in each bottle.
- 7 Label fully with clinical details, antibiotics currently being administered to the patient and the time and date of the sample. Some organisations require the barcode attached to the culture bottles to be removed and either placed in the patient notes or attached to the request form. Check for local guidance.

## Femoral venous access

This is used when alternative veins are unsuitable for phlebotomy, such as if the upper limbs are not accessible, if infection is present or if the patient simply has poor veins for venepuncture.

### Anatomy of the femoral triangle

It is important to know the anatomy of the femoral triangle when attempting a femoral stab. It is a space found in the groin, demarcated medially by the adductor longus muscle edge (apparent by flexion, abduction and laterally rotation of the thigh), laterally by sartorius and superiorly by the inguinal ligament (this runs between the pubic tubercle and the anterior superior iliac spine). The femoral artery, nerve and vein are all found within the femoral triangle (Figure 5.9).

### Sampling

- 1 Sampling is obtained using a 21G needle and a 20-mL syringe.
- 2 Palpate for the femoral artery; the femoral vein lies medial to this.
- 3 Wipe the skin with an antiseptic wipe (2% chlorhexidine/70% alcohol) and allow the skin to dry.
- 4 Insert the needle approximately 1 cm medial to the femoral artery, and at 90° to the skin, withdrawing the plunger as you advance the needle.

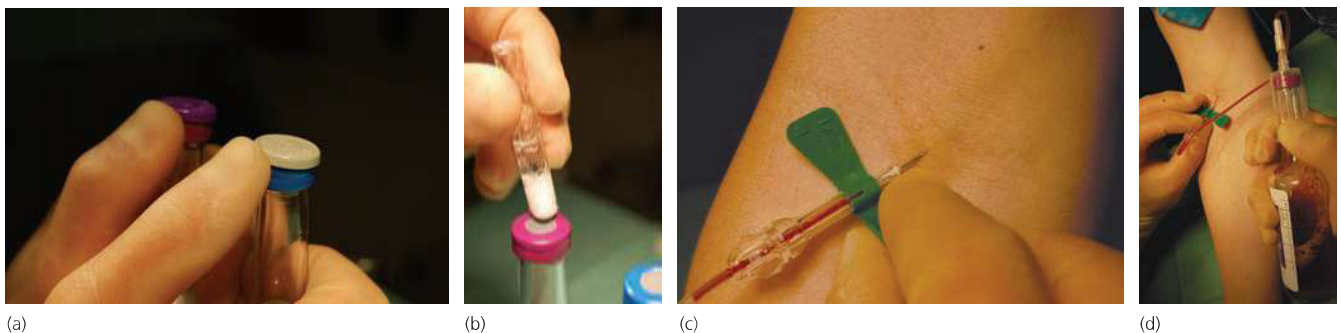
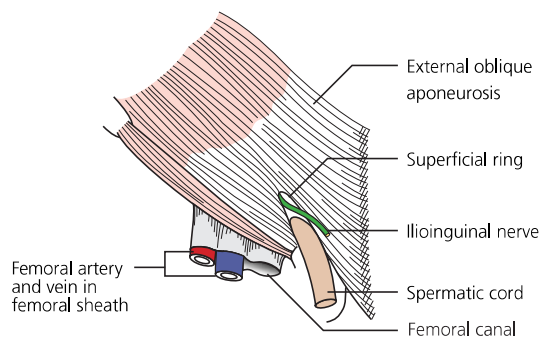


Figure 5.8 Step-by-step guide: blood cultures. (a) Removing the tops of culture bottles. (b) Cleaning the tops of blood culture bottles using 2% chlorhexidine in 70% alcohol solution. (c) A butterfly needle inserted into a vein. (d) A blood culture sample being taken.



**Figure 5.9** Anatomy of the femoral artery. (From Faiz O, Moffat D. (2006) *Anatomy at a Glance*, 2nd edn. Blackwell Publishing, Oxford, with permission.)

## Further reading

- Bache J, Armit C, Gadd C. (1998) *Practical Procedures in the Emergency Department*. Mosby, Oxford.
- Lumley JS. (2002) *Surface Anatomy. The Anatomical Basis of Clinical Examination*, 3rd edn. Churchill Livingstone, Edinburgh.
- Marbat LL, Case E. (2004) *Clinical Procedures. Blueprints*. Blackwell Publishing, Oxford.
- Moore KL, Dalley AF. (1999) *Clinically Orientated Anatomy*, 4th edn. Lippincott Williams & Wilkins, Philadelphia.

- 5 Once flashback is achieved, stop advancing the needle and withdraw the plunger to collect the required blood.
- 6 Following collection, withdraw the needle, apply pressure over the access site using cotton wool and distribute the blood into the required bottles.

### Handy hints/troubleshooting

- If using the needle and syringe technique, loosen the plunger several times before taking the blood – this should avoid the plunger sticking.
- Encourage venodilation by asking the patient to repetitively clench and release his or her fist, and by gently tapping on the vein.
- Tether the skin with your spare hand to help fix the vein.
- Consider whether a cannula is also needed – if so, blood can be taken from the cannula after insertion, by using either a Vacutainer™ technique or a needle and syringe (see Chapter 10).
- Take great care when labelling cross-match and group and save samples – the smallest of errors can make the sample void. Always handwrite these samples and include all the patient's details.
- Remember femoral triangle anatomy with the acronym NAVY – from lateral to medial there is *n*erve, *a*rtery, *v*ein and then *Y*-fronts!
- Include as much clinical information on the forms as possible, especially microbiology forms.